Mass Veterinary Services

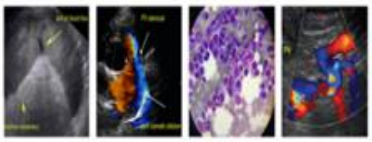

SonoPath
Clinical Sonography & Telecytology
EDUCATIONAL TELECONSULTATION SERVICES™
1-800-838-4268 info@sonopath.com SonoPath.com

PATIENT
Oliver Jones

SPECIES
Canine

BREED
Cavalier

SEX
Male Neutered

AGE
8 years

WEIGHT
32.5lbs

INTERPRETED BY
Maggie Machen Lamy, DVM DACVIM (Cardiology)

IMAGING PERFORMED BY
Pamela Harrigan, RDCS

HOSPITAL NAME
Mass Veterinary Services

REFERRING VET
Dr. Masloski

INVOICE
24263

DATE
5/18/22

PRESENTING CLINICAL SIGNS

History: Oliver was noted to have a heart murmur in April when he was seen for a cough. Significant coughing when excited or when he first gets up. Cough has improved since started on Pimobendan. Oliver's appetite is very good. He is no longer being taken for walks to avoid stress on his heart. He does continue to have some spurts of energy but overall is more lethargic than he previously was. On exam today: NSR, grade IV/VI murmur with PMI left apical area radiating to right, PSS, lung fields clear. BP: >300 mmHg. Current medications: 1) Apoquel 16mg 1/2 tab daily 2) Pimobendan/vetmedin 2.5mg 1 tab twice a day *No sedation for study.

ECHOCARDIOGRAM FINDINGS

2D, m-mode, color flow and Doppler imaging is available.
Left ventricle: The LV diameter is increased with hyperdynamic myocardial function. Subtle septal flattening in end systole. LV wall thicknesses are decreased.
Left atrium: The left atrium is severely dilated.
Mitral valve: Diffuse thickening of mitral valve leaflets with prolapse into the left atrial lumen. Lack of coaptation in systole. Severe eccentric mitral regurgitation, normal velocity.
Aortic valve/Aorta: The aortic valve is normal in morphology and mobility. Normal aortic outflow velocity; laminar flow. No aortic insufficiency.
Right ventricle: Mild RV dilation.
Right atrium: Mild RA dilation.
Tricuspid valve: The tricuspid valve appears mildly thickened with mild to moderate tricuspid regurgitation. TR velocity is elevated consistent with severe pulmonary hypertension (PG: >80mmHg).
Pulmonic valve/Pulmonary artery: The pulmonic valve is normal in morphology and mobility. Mild MPA dilation. Normal pulmonic outflow velocities. No pulmonic insufficiency.
Pericardium/other: No pericardial or pleural effusion noted. No obvious cardiac masses.
Heart rhythm: ECG reveals a sinus rhythm with an average HR of 140bpm.

2-Dimensional Measurements

Ao diam (cm)	2.1
LA diam (cm)	4.3
LA:Ao (Swe)	2.0
IVS thickness (cm)	0.69
LVID diastole (cm)	4.6
PW thickness (cm)	0.64
LVID systole (cm)	2.3
FS (%)	50

Doppler Measurements

PV Vmax (m/s)	0.42
AoV Vmax (m/s)	1.3
MR Vmax (m/s)	NA
TR Vmax (m/s)	4.8
TR PG (mmHg)	92

INTERPRETATION OF THE FINDINGS

The murmur is due to chronic degenerative valve disease causing severe mitral and mild to moderate tricuspid regurgitation. Severe left atrial and ventricular enlargement indicate the risk for spontaneous congestive heart failure is elevated. Severe pulmonary hypertension is noted, which is likely secondary to a combination of underlying airway disease and chronically elevated LA pressure. This has led to mild right heart dilation as well. No obvious additional issues such as systolic dysfunction are noted.

Mass Veterinary Services

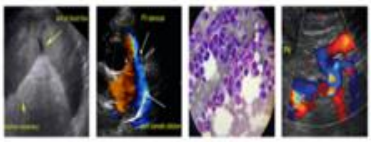

SonoPath
Clinical Sonography & Telecytology
EDUCATIONAL TELECONSULTATION SERVICES™
1-800-838-4268 info@sonopath.com SonoPath.com

PATIENT
Oliver Jones

SPECIES
Canine

BREED
Cavalier

SEX
Male Neutered

AGE
8 years

WEIGHT
32.5lbs

INTERPRETED BY
Maggie Machen Lamy, DVM DACVIM (Cardiology)

IMAGING PERFORMED BY
Pamela Harrigan, RDCS

HOSPITAL NAME
Mass Veterinary Services

REFERRING VET
Dr. Masloski

INVOICE
24263

DATE
5/18/22

Given the degree of disease seen here and a reported cough, recommend full cardiac supportive medications as below including low dose Lasix. Baseline chest radiographs are highly recommended to determine if CHF is present; however, I would utilize Lasix regardless. Additionally, severe PAH warrants Sildenafil therapy, even in the absence of clinical dyspnea/syncope.

Monitoring of sleeping breathing rates is recommended as the best way to screen for CHF at home. Monitoring for symptoms of PAH is suggested, including exertional syncope or dyspnea. Adequate cough suppression is also of the upmost importance, utilizing hydrocodone PRN.

Long term prognosis is guarded to poor; however, I am hopeful we can stabilize the patient for some time on medications. Once CHF develops, they are generally able to maintain a good quality of life for an average of 8-12 months. Patient will always be at risk for progression to CHF, development of arrhythmias/LA tear, syncope and/or sudden death in the future.

The reported blood pressure is elevated and should be reassessed for accuracy particularly given no reported clinical signs of severe hypertension (retinal changes, etc.) or evidence of LVH on echo. Ideally obtain serial measurements in a controlled, low stress environment and continue until 3 consecutive readings plateau within 5mmHg of variability. If persistently >180mmHg despite a relatively calm demeanor, recommend institution of amlodipine to effect. Additionally, if deemed accurate, screening for predisposing underlying causes of SHT is recommended (Cushings, PLN, adrenal tumor, etc.), as primary disease is relatively uncommon and a rule out diagnosis.

RECOMMENDATIONS

- Institute Lasix 1-2mg/kg PO q12h.
- Institute ACE 0.5mg/kg PO q12h.
- Continue Pimobendan 0.3mg/kg PO q12h.
- Institute Spironolactone 1-2mg/kg PO q12h.
- Institute Sildenafil 1-2mg/kg PO q12h.
- Consider hydrocodone with homatropine instead of cough tabs for QOL if needed (0.2-0.4mg/kg PO up to q4-6 hours PRN for cough; available in 5/1.5mg tabs and 5mg/5ml liquid suspension).
- Reassess BP as discussed.
- Baseline chest radiographs are highly recommended, particularly if cough does not respond to therapy.
- Elective anesthesia is not advised.
- Omega fatty acid supplementation and mild salt restriction may be of some long-term benefit.
- Monitor for development of a cough, labored breathing, exercise intolerance or collapse episodes. Monitoring of sleeping breathing rates is the best way to screen for progression to CHF at home.

PLAN

- A recheck echocardiogram is recommended in 6 months to screen for progression, sooner if clinical signs arise.

Mass Veterinary Services

SonoPath
Clinical Sonography & Telecytology
EDUCATIONAL TELECONSULTATION SERVICES™
1-800-838-4268 info@sonopath.com SonoPath.com

PATIENT
Oliver Jones

SPECIES
Canine

BREED
Cavalier

SEX
Male Neutered

AGE
8 years

WEIGHT
32.5lbs

INTERPRETED BY
Maggie Machen Lamy, DVM DACVIM (Cardiology)

IMAGING PERFORMED BY
Pamela Harrigan, RDCS

HOSPITAL NAME
Mass Veterinary Services

REFERRING VET
Dr. Masloski

INVOICE
24263

DATE
5/18/22

IMAGES

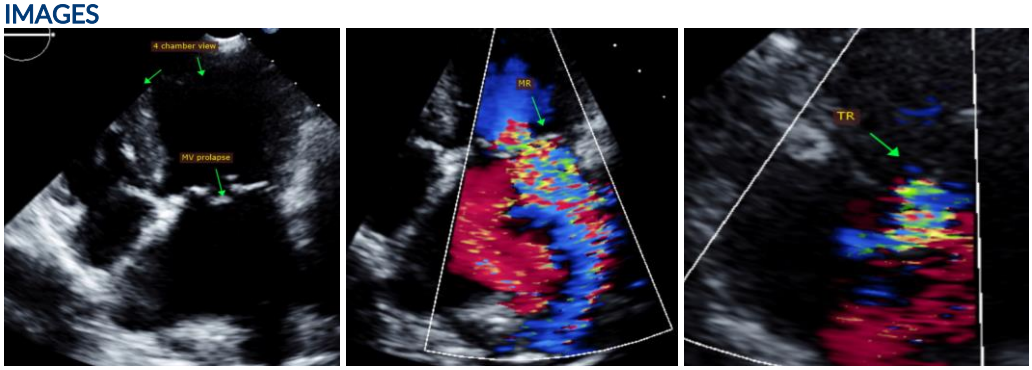

The information and recommendations provided are based on the images presented by the referring veterinarian. No evaluation can be communicated regarding pathology that was not visible in the image/video clips provided.

Thank you for this referral. This report was generated using transcription software, and minor dictation errors may be present. If the clinical or image interpretation does not parallel your findings or if I can be of any further assistance, please contact me.

Maggie Machen Lamy, DVM
Diplomate of the American College of Veterinary Internal Medicine (Cardiology)
info@sonopath.com

Echocardiogram performed by: Pamela Harrigan, RDCS
Pet Animal Ultrasound Service (4paus.com)